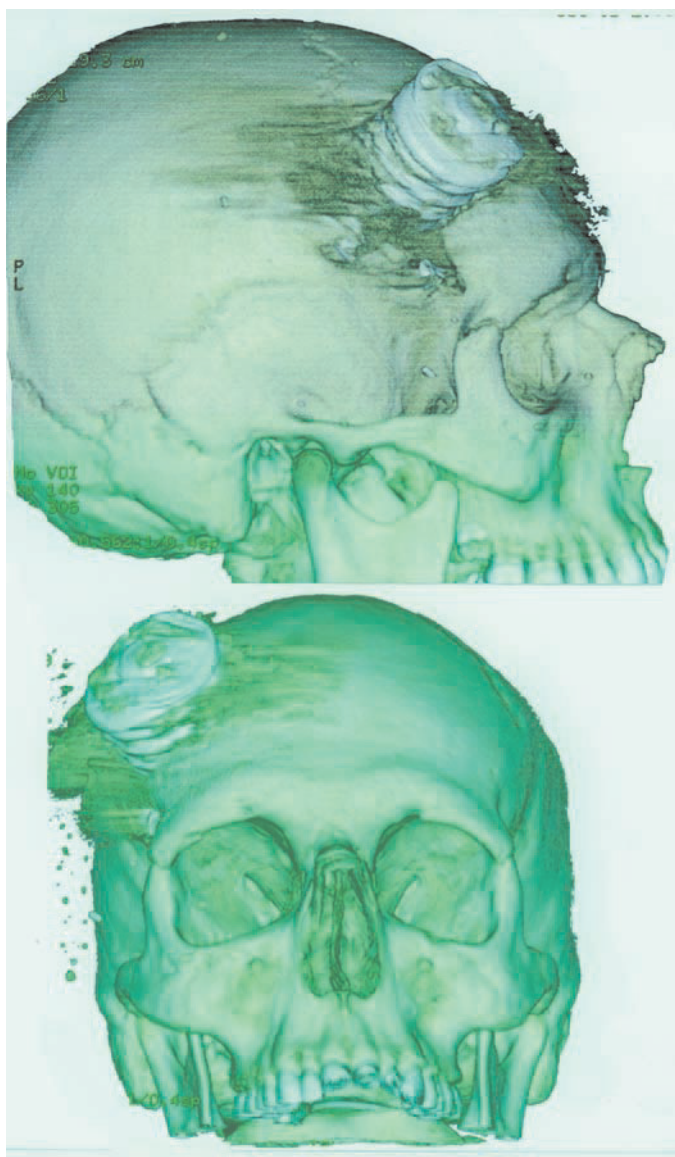


Valve-spring headache



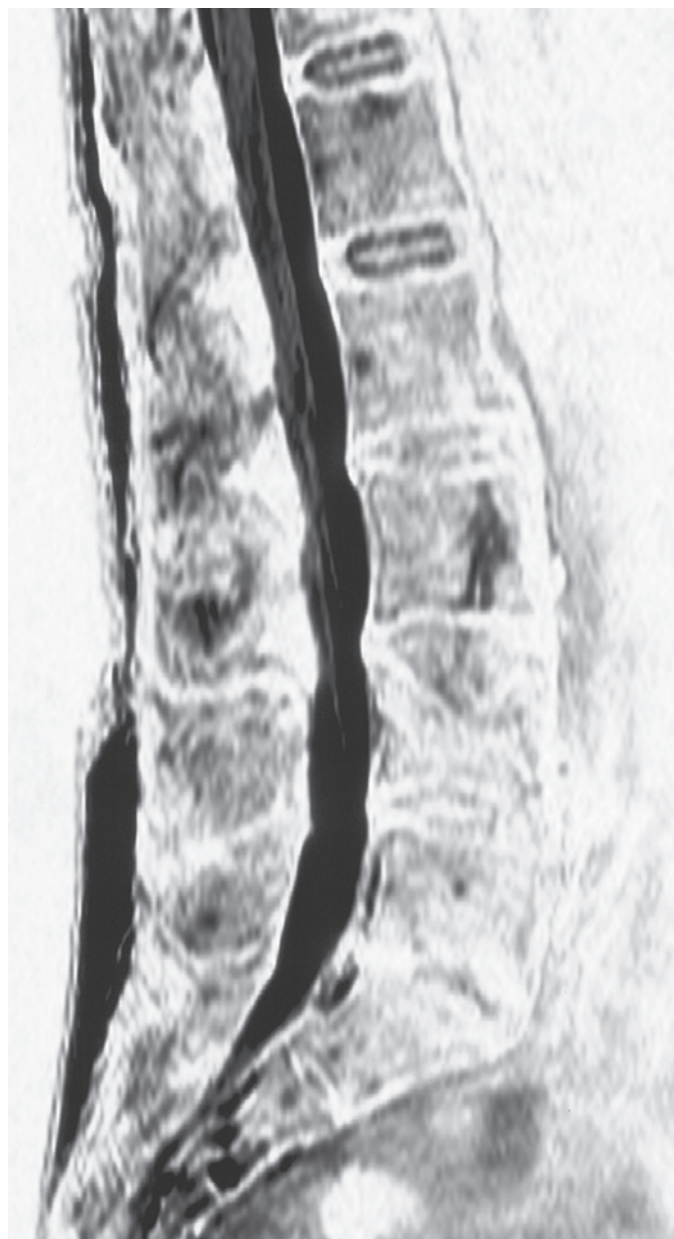
3D reconstructed image from a multidetector computed tomography scan of the head.

This unfortunate patient was involved in a motor vehicle accident. Being an old car there were no airbags, and valve springs are obviously a poor substitute.

Sam McCormack

Radiology Registrar, Royal Prince Alfred Hospital
Camperdown, NSW
mccormacksam@optusnet.com.au

Little boy lost



We were wondering how to describe the lesion seen on this magnetic resonance image. Vertebral “body” seemed appropriate.

Brad Milner

Radiology Registrar, Department of Radiology
Liverpool Hospital, Liverpool, NSW
brad_milner2001@yahoo.com.au